

SCENARIO OF DIABETIC RETINOPATHY

T. Janani Priya, Dr.Savithri.V
M.Sc., Computer Science and Technology,
Women's Christian College, Nungambakkam,
Chennai, TamilNadu, India.
janutpri@gmail.com

ABSTRACT: Nearly 80% of the population in India affected with Diabetic retinopathy. Diabetic Retinopathy is an eye condition that affects people with diabetes who have high blood glucose, or sugar, over a prolonged period of time. The objective of this study is to detect diabetic retinopathy in early stage by applying systematic approach by inputting fundus image, converting image into gray-scale and enhancement of the image. Extraction of retinal features through edge detection techniques. Dilation and erosion method is applied for extracting exudates. Detects abnormal retinal features using match features template. This technique helps to accurate analysis of the severity of proliferated disease. This helps the ophthalmologist to diagnose the stages of disease severity.

Keywords: detection of hard exudates, edge detection, morphological methods and identifying different stages of diabetic retinopathy.

----- ◆ -----

1. INTRODUCTION

Diabetic retinopathy (DR) is caused by changes in the blood vessels of the retina. When these blood vessels are damaged, they may leak blood and grow fragile new vessels. When the nerve cells are damaged, vision is impaired. Diabetic retinopathy is the most common diabetic eye disease and a leading cause of blindness. The exact mechanism by which diabetes leads to DR is not fully understood. Micro vascular occlusion causes retinal ischemia leading to arteriovenous shunts and neo vascularization. Leakage results in intraretinal hemorrhages and localized or diffuse oedema. These processes result in the characteristic features seen at various stages of DR: Microaneurysms - physical weakening of the capillary walls which predisposes them to leakages. Hard exudate precipitates of lipoproteins or other proteins leaking from retinal blood vessels. Hemorrhages - rupture of weakened capillaries, appearing as small dots/larger blots or 'flame' hemorrhages that track along nerve-fiber bundles in superficial retinal layers (the haemorrhage arises from larger and more superficial arterioles). Cotton wool spots - build-up of axonal debris due to poor axonal metabolism at the margins of ischemic infarcts. Neovascularisation is an attempt (by residual healthy retina) to revascularise hypoxic retinal tissue. The classification of DR is based on which part of the retina is affected and the degree of pathology seen on slit-lamp examination of the eye. It is not necessarily correlated to the degree of vision, which may be almost normal until the very late stages of the disease when little can be done to save it. The aim is to identify signs of diabetic retinopathy with eye images.

2. LITERATURE REVIEW

There are several approaches for Diabetic Retinopathy detection and classification. Researchers have been working in the area of image processing for early detection of Diabetic Retinopathy

many techniques like mathematical morphology, edge detection, pattern recognition, Cohen's kappa method, texture identification, image enhancement, image segmentation, sobel filter, thresholding are helpful for identifying blood vessels, hard exudates, microaneurysms, hemorrhages from the fundus image.[1] Extraction of blood vessels using edge detection.[2] Detection of microaneurysms using Cohen's Kappa method and algorithms. [3] Ophthalmologists recognize diabetic retinopathy based on features, such as blood vessel area, exudes, hemorrhages, microaneurysms and texture. In their paper they review region growing algorithms used for the extraction of these features from digital fundus images. [4] Screening conducted over a larger population can become efficient if the system can separate normal and abnormal cases, instead of the manual examination of all images. Their paper reviews various methods like Pre-processing for contrast enhancement and removal of noise detection, Localization of the Optic Disc and its segmentation, Retinal vascular tree segmentation, Localization of fovea region, Abnormal Feature Extraction. [5] Extraction of blood vessels by entropy thresholding method and optic disc using sobel filter method. Then the thresholding method is employed to segment the exudates in diabetic retinopathy images. [7] Their work, morphological image processing and support vector machine (SVM) techniques were used for the automatic diagnosis of eye health. They have used 331 fundus images for analysis. [9] Comparison of computer vision with human detection of retinal lesions was made. The computer system has been developed using image processing and pattern recognition techniques to detect early lesions of diabetic retinopathy. The performance of the computer vision system in diagnosing early retinal lesions was comparable with that of human experts. [10] Image preprocessing, morphological processing techniques and texture analysis methods are applied on the fundus images to detect the features such as area of

hard exudates, area of the blood vessels and the contrast. [12] Recursive region growing segmentation algorithms combined with the use of a new technique, termed a 'Moat Operator', were used to automatically detect features of Non proliferated diabetic retinopathy. [13] A new method for fovea localization based on alternating sequential filtering and morphological methods have been discussed and implemented. Region growing algorithms for exudates and hemorrhage detection have been presented. [14] Determination of Optic Disk and its centre. They find the brightest part of the fundus and apply Hough transform. The detection of fovea is done by using its spatial relationship with optic disk. Exudates are found using their high grey level variation and their contours are determined by means of morphological reconstruction techniques. The blood vessels are highlighted using bottom hat transform and morphological dilation after edge detection. All the enhanced features are then combined in the fundus image for the detection of Diabetic retinopathy. [20] Detection of fovea using Filtering and statistical adaptive thresholding. [21] Detection of Diabetic retinopathy using shape matching algorithm and match filter method. [22] Their work examines on digital image processing in the field of early detection of Diabetic retinopathy using fundus photographs. Algorithms were categorized into 5 group image preprocessing, localization and segmentation of the optic disk, segmentation of the retinal vasculature, localization of the macula and fovea using match filter, localization and segmentation of diabetic retinopathy pathologies. [24] Quantitative techniques, image segmentation, morphological methods and image enhancements have been used to detect the retinal lesions.

3. METHODOLOGY

The methodology of the survey is given below. Here the fundus image of the eye is given as input. Then the filtering of the input image is filtered. Gray scale image is taken as input for image dilation and erosion method to identify the exudates. Edge of the image is detected using canny detector. Then the image is segmented. Then the image features is matched using match feature technique

Step1: Input Fundus Images

Read the input image from Fundus camera. The Fundus camera is more reliable, non-invasive and easy to use compared to traditional ophthalmoscopy. The Fundus, or inner lining, of the eye is photographed with specially designed cameras through the dilated pupil of the patient. The painless procedure produces a sharp view of the retina, the retinal vasculature, and the optic nerve head (optic disc) from which the retinal vessels enter the eye. Color Fundus Photography is used to record the condition of these structures in order to document the presence of disorders and monitor their change over time. The eye fundus photography results in a better sensitivity rate i.e, a better detection rate of abnormal eye fundus.

Step2: Image Pre-processing

Image Pre processing includes various techniques such as contrast enhancement, gray component, image de-noising etc. Initially we convert the RGB image into gray scale image to further process the image. Image pre-processing can significantly increase the reliabil-

ity of an optical inspection. Several filter operations which intensify or reduce certain image details enable an easier or faster evaluation. Users are able to optimize a camera image with just a few clicks.

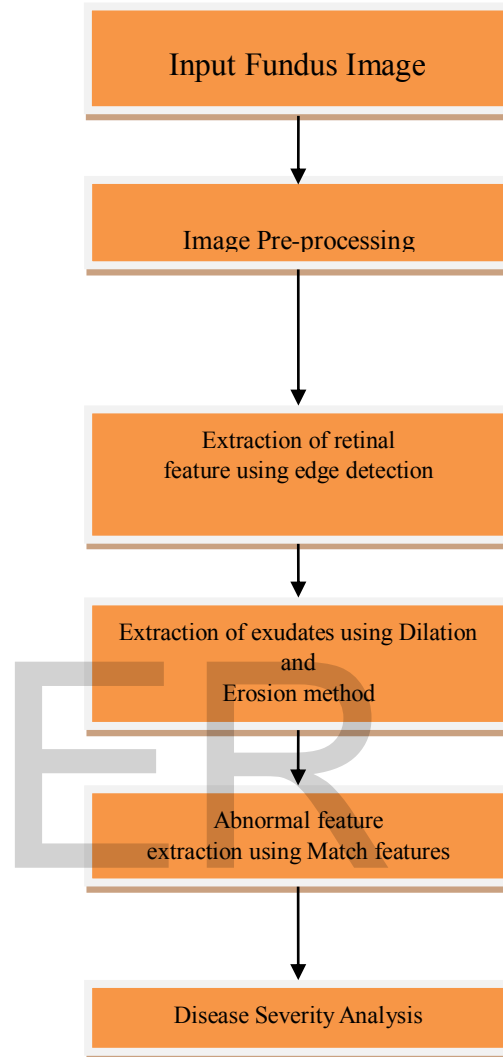


Figure 1: Proposed System

Step3: Extraction of retinal features

In the RGB images the green channel exhibits the best contrast between the vessels and background while the red and blue ones tends to be more noisy. Since the retinal blood vessels appear darker in gray image, the green channel is used to convert the intensity of the image. Filtering is used to remove the noise which gets added into the fundus image.

Step4: Extraction of Exudates

Hard exudates are yellow spots seen in the retina, usually in the posterior pole near the macula. They are lipid break-down products that are left behind after localized edema resolves. They indicate increased vessel permeability, a connected risk of retinal edema and fluid accumulation in the retina. Dilation and erosion method is used to find the exudates in the retina.

Step5: Abnormal features extraction using Shape matching algorithm

The yellow spots of exudates in the retina are spotted in the image using shape matching algorithm which is combined with the dilation and erosion method to reduce the intensity of the image to give a clear image to view the exudates. Match features are used to compare the normal eye image with proliferated eye image to detect Diabetic retinopathy. Only the affected regions of the retina are highlighted.

Step6: Disease Severity Analysis

Based on the images obtained has output. The images are categorized into four types: Normal, Mild, Non-proliferated, Proliferated and Severe.

The proposed system helps to convert the image to dilated and eroded image and the first property output helps to find the exudates. Future work is to enhance the code and render the exudates image. Further evaluation will be undertaken in order to be able to integrate the presented algorithm in a tool for diabetic retinopathy diagnosis.

4 CODING

```
% READ IMAGES
a = imread('severe4.jpg');

%display coloured version(original)
figure,imshow(a);

% convert to grayscale
grayeye1 =rgb2gray(a);

% display grayscale

title('input image');
figure,imshow(grayeye1);
dgrayeye1 = imadjust(grayeye1,[0.1 0.9],[]);
title('grayscale image made darker');
figure,imshow(dgrayeye1);
se = strel('disk',1);

%canny eye obtaining
cannyeye = edge(dgrayeye1,'canny',0.15);
title('cannyeye image');
figure,imshow(cannyeye);

%dilate the cannyeye image
dilate = imdilate(cannyeye,se);
title('dilated image');
figure, imshow(dilate);

% dilation and erosion
clear all
clc
a=imread('severe4.jpg');
p=size(a);
```

%%%% using in built MATLAB function %%%

```
s=strel('square',3);
d1=imdilate(a,s);
d2=imerode(a,s);

%%%% Writing program
w=[1 1 1;1 1 1;1 1 1];
for x=2:1:p(1)-1
    for y=2:1:p(2)-1
        a1=[w(1)*a(x-1,y-1) w(2)*a(x-1,y) w(3)*a(x-1,y+1)
w(4)*a(x,y-1) w(5)*a(x,y) w(6)*a(x,y+1) w(7)*a(x+1,y-1)
w(8)*a(x+1,y) w(9)*a(x+1,y+1)];
        A1(x,y)=max(a1); %Dilation%
        A2(x,y)=min(a1); % Erosion%
    end
end

b=imread('normale1.jpg');
I1 = rgb2gray(b);
I2 = rgb2gray(a);

%Find the corners.
points1 = detectHarrisFeatures(I1);
points2 = detectHarrisFeatures(I2);

%Extract the neighborhood features.
[features1, valid_points1] = extractFeatures(I1, points1);
[features2, valid_points2] = extractFeatures(I2, points2);

%Match the features.
indexPairs = matchFeatures(features1, features2);


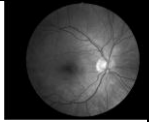
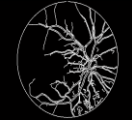

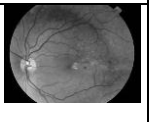


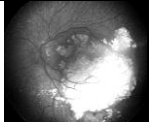

%Retrieve the locations of the corresponding points for each image.
matchedPoints1 = valid_points1(indexPairs(:, 1), :);
matchedPoints2 = valid_points2(indexPairs(:, 2), :);

%Visualize the corresponding points. You can see the effect of translation between the two images despite several erroneous matches.

figure; showMatchedFeatures(I1, I2, matchedPoints1,
matchedPoints2);
title('exudates are pointed image');
figure ,imshow(a);
title('Mild Affected Eye Image');
figure,imshow(b);
figure,imshow(d1)
title('Dilation with inbuilt function');
figure,imshow(d2)
title('Erosion with inbuilt function');
figure,imshow(A1)
title('Dilation ');
figure,imshow(A2)
```

5 TABLE OF CONTENTS

The output is listed below as a tabular column for clear understanding.

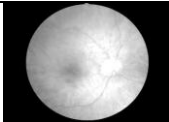
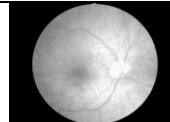
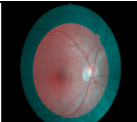
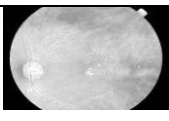
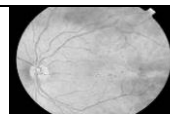
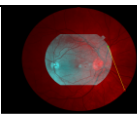
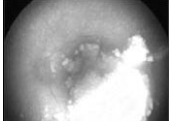
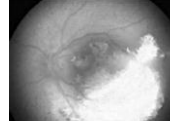
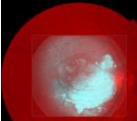
Methods/Types	Color Image	Gray-Scale	Binary Image
Normal Eye			
Mild Eye			
Severe			

6. CONCLUSION

In this paper, the different stages of diabetic retinopathy is detected using image processing techniques such as image enhancement, segmentation, histogram, edge detection and morphological images which are applied on the fundus image to detect the exudates. The abnormalities that cannot be seen via the indiscernible can be detected accurately. The proliferated and severity of the fundus image helps the ophthalmologist to determine patient stage of Diabetic Retinopathy.

REFERENCES

- [1]R.ManjulaSri, M.Raghupathy Reddy, and K.M.M.Rao, Image Processing for Identifying Different Stages of Diabetic Retinopathy, ACEEE -Vol. 11, June 2014
- [2]Sergey Ovcharenko ,Rasim Akhunzyanov ,2015. Diabetic Retinopathy Detection.
- [3]Oliver Faust & Rajendra Acharya U. & E. Y. K. Ng & Kwan-Hoong Ng & Jasjit S. Suri, 2010. Algorithms for the Automated Detection of Diabetic Retinopathy Using Digital Fundus Images: A Review
- [4]Madhura Jagannath Paranjpe, M N Kakatkar,2014 .Review of methods for diabetic retinopathy detection and severity classification IJRET eISSN: 2319-1163 | pISSN: 2321-7308 Vol 03.
- [5]Soumil Chugh, Jaskirat Kaur, Deepti Mittal.Vol. 3 - Issue 10 2014.Exudates Segmentation in Retinal Fundus Images for the Detection of Diabetic Retinopathy. IJERT e-ISSN: 2278-0181
- [6]Review of Automated Detection for Diabetes Retinopathy Using Fundus Images Raju Maher, Sangramsing Kayte, Dr. Mukta Dhopeshwarkar Volume 5, Issue 3, March 2015
- [7]Acharya, U. R., Lim, C. M., Ng, E. Y. K., Chee, C., and Tamura, T., Computer based detection of diabetes retinopathy stages using digital fundus images. J. Eng. Med. 223(H5):545–553, 2009.
- [8]Larsen, M., Godt, J., Larsen, N., Lund-Andersen, H., Sjolie, A. K., Agardh, E., Kalm, H., Grunkin, M., and Owens, D. R., Automated detection of fundus photographic red lesions in diabetic retinopathy. Invest. Ophthalmol. Vis. Sci. 44(2):761–766, 2003.
- [9]Lee, S. C., Lee, E. T., Kingsley, R. M., Wang, Y., Russell, D., Klein, R., and Warn, A., Comparison of diagnosis of early retinal lesions of diabetic retinopathy between a computer system and human experts. Arch. Ophthalmol. 119(4):509–515, 2001.
- [10]Nayak, J., Bhat, P. S., Acharya, U. R., Lim, C. M., and Kagathi,

Methods /Types	Dilated Image	Eroded Image	Image Features Matched
Normal Eye			
Mild Eye			
Severe			

The results obtained and the severities of the disease are tabulated at the end of this paper. Depending on the severity, there are three categories such as mild, moderate and severe stage. A treatment can also be based on the severity. Certain known treatments are Vitrectomy, Scatter laser treatment, Focal laser treatment and Laser photocoagulation

- M., Automated identification of different stages of diabetic retinopathy using digital fundus images. *J. Med. Syst.*, USA, 32 (2):107–115, 2008.
- [11] Niemeijer, M., van Ginneken, B., Staal, J., Suttorp-Schulten, M., and Abramoff, M., Automatic detection of red lesions in digital color fundus photographs. *IEEE Trans. Med. Imag.* 24(5):584–592, 2005.
- [12] Sinthanayothin, C., Boyce, J. F., Williamson, T. H., and Cook, H. L., Automated detection of diabetic retinopathy on digital fundus image. *Diabet. Med.* 19(2):105–112, 2002.
- [13] Chitra Raju I, Lizy Abraham, 2015. Detection of Lesions in Color Fundus Images for Diabetic Retinopathy Grading, (IJEAT) ISSN: 2249 – 8958, Vol-4.
- [14] Noronha, K., Nayak, J., and Bhat, S. Enhancement of retinal fundus image to highlight the features for detection of abnormal eyes. In *Proceedings of the IEEE Region10 Conference (TENCON2006)* (2006)
- [15] A.S. Neubauer, C. Chryssafis, M. Thiel, S. Priglinger, U. Welge-Lüssen, A. Kampik, Screening for diabetic retinopathy and optic disc topography with the “retinal thickness analyzer” (RTA), *Ophthalmology* 102 (2005) 251–258
- [16] P.Kahai, K.R. Namuduri, H. Thompson, A decision support framework for automated screening of diabetic retinopathy, *Int. J. Biomed. Imag.* (2006).
- [17] S.C. Lee, E.T. Lee, Y. Wang, R. Klein, R.M. Kingsley, A. Warn, Computer classification of non-proliferative diabetic retinopathy, *Arch.Ophthalmol.* 123 (2005) 759–764.
- [18] Jelinek HF, Cree MJ, Leandro JJG, Soares JVB, Cesar RM, Luckie A. Automated segmentation of retinal blood vessels and identification of proliferative diabetic retinopathy. *Journal of the Optical Society of America A.* 2007;24(5):1448–1456. [PubMed]
- [19] Ege, B. M., Hejlesen, O. K., Larsen, O. V., Møller, K., Jennings, B., Kerr, D., and Cavan, D. A., Screening for diabetic retinopathy using computer based image analysis and statistical classification. *Comput. Methods Programs Biomed.* 62(3):165–175, 2000.
- [20] Estabridis K, de Figueiredo RJP, Automatic detection and diagnosis of diabetic retinopathy. *IEEE Int. Conf. Image Processing, ICIP 2007.*
- [21] Shape Matching: Similarity Measures and Algorithms, Remco C. Veltkamp, Dept. Computing Science, Utrecht University Padualaan 14, 3584 CH Utrecht, The Netherlands
Remco.
- [22] Detection of Diabetic Retinopathy in Fundus Photographs ,Pavle Prentasić. University of Zagreb, Faculty of Electrical Engineering and Computing, Unska 3, 10000 Zagreb, Croatia
- [23] Retinal image analysis: Concepts, applications and potential Niall Pattona, Tariq M. Aslamc, Thomas MacGillivrayd ,Jan J. Dearye , Baljean Dhillonb ,Robert H. Eikelboomf, Kanagasingam Yogesana ,Jan J. Constable , *Progress in Retinal and Eye Research* 25 (2006) 99–127.
- [24] Retinal Imaging and Image Analysis, Michael D. Abramoff, Senior Member, IEEE, Mona K. Garvin, Member, IEEE, and Milan Sonka, *IEEE Trans Med Imaging.* 2010 Jan 1; 3: 169–208. doi: 10.1109/RBME.2010.2084567
- [25] Identification of diabetic retinopathy stages in human retinal image A.Alaimahal, Dr.S.Vasuki. *IJAR CET Volume 2, Issue 2, February 2013.*
- [26] A Simple and Fast Algorithm to Detect the Fovea Region in Fundus Retinal Image Soumitra Samanta¹, Sanjoy Kumar Saha² and Bhabatosh Chanda¹, 978-0-7695-4329-1/11 \$26.00 © 2011 IEEE DOI 10.1109/EAIT.2011.22
- [27] Retinal Image Analysis for Exudates Detection, I. Kullayamma, P. Madhava Latha, (IJERA) ISSN: 2248-9622 Vol. 3, Issue 1, January -February 2013, pp.1871-1875.
- [28] Fine Exudate Detection using Morphological Reconstruction Enhancement, Akara SOPHARAK, Bunyarit UYYANONVARA, Sarah BARMAN, Sakchai VONGKITTIRUX, and Nattapol WONGKAMCHANG, *IJEAT* :ISSN: 2249 – 8958, Vol-10.
- [29] Automated Detection and Quantification of Haemorrhages in Diabetic Retinopathy Images Using Image Arithmetic and Mathematical Morphology Methods, Joshi Manisha Shivaram, Dr.Rekha Patil, Dr. Aravind H, *International Journal of Recent Trends in Engineering*, Vol 2, No. 6, November 2009
- [30] A Novel Algorithm for Exudates Detection Using Matlab, Kalashree S, Sowmya K S, *IJARCSSE* , Volume 5, Issue 2, Feb 2015.